



ISSN Print: 2394-7489
ISSN Online: 2394-7497
IJADS 2021; 7(2): 561-563
© 2021 IJADS
www.oraljournal.com
Received: 07-02-2021
Accepted: 09-03-2021

Dr. Altaf Hussain Chalkoo
Professor and Head, Department
of Oral Medicine and Radiology,
GDS Srinagar, Jammu and
Kashmir, India

Shamshad Begum
Tutor, Department of Oral
Medicine and Radiology, GDS
Srinagar, Jammu and Kashmir,
India

Association between oral lichen planus and hepatitis C virus infection among Kashmir population

Dr. Altaf Hussain Chalkoo and Shamshad Begum

DOI: <https://doi.org/10.22271/oral.2021.v7.i2i.1263>

Abstract

Group 1 consisted of 175 patients with oral lichen planus lesions. Prevalance of HCV infection was carried out. Group 2 was composed of 24 patients with known and confirmed diagnosis of HCV infection. In this group prevalence of OLP lesion was carried out. Prevalence of HCV infection in oral lichen planus patients (Group 1) was found in only 1.7% of cases and overall frequency of OLP in HCV patients (group 2) was 4.1%. No correlation was seen in both groups because the overall frequencies of both diseases were very less and insignificant with their respective control groups.

Keywords: hepatitis C virus, oral lichen planus, wickham striae, cytotoxic CD8+ T cells

Introduction

Lichen planus is defined as a mucocutaneous disorder that affects oral and genital mucous membranes, skin, nails, and scalp. It is a common skin disease with frequently involving oral mucosa [1]. It affects 1–2% of the whole population [2]. Oral lichen planus usually present on buccal mucosa, lip, gingival, tongue and floor of the mouth. The lesions contain both red and white component in which white lines are lattice-like intersecting to each other called Wickham striae overlies on red component. There are several clinical forms of LP; reticular, annular, atrophic/erythematous, erosive/ulcerative, papular, plaques-like and bullous type [3].

The etiopathogenesis is not fully understood. In most of the cases, it is idiopathic but T-cell-mediated immune response has a primary role in emergence of this disease. Activation of cytotoxic CD8+ T cells that leads to basal keratinocytes liquefaction degeneration and apoptosis [4].

OLP also associated with numerous systemic disorders such as diabetes mellitus (DM), hypertension, psychosomatic disorders, metabolic syndrome, thyroid diseases, chronic liver disease (hepatitis B and C), gastrointestinal diseases and immunosuppression.⁵ HCV infection is considered as one of the major cause of chronic liver disease effecting approximately 3% of the world population [6]. Numerous studies have been carried out in order to find out the association of oral lichen planus with Hepatitis C virus infection. Studies done by Mokni M *et al.* 1991, Sebastian *et al.* 1992, Criber *et al.* 1994, Pervez *et al.* 1996, Nago *et al.* 1997, Imhof *et al.* 1997, Bagan *et al.* 1998, Figueredo *et al.* 2002, Ghodsi *et al.* 2004, Konidena *et al.* 2011, Alves *et al.* 2011, Corrozzo *et al.* 2014 and Vanzela *et al.* 2017 showed strong association of HCV and OLP [5].

Aim

The aim of this study was to investigate any possible association between Oral Lichen Planus and Hepatitis C in Kashmir population.

Study Design and Methodology: This prospective study had done in the Post Graduate Department of Oral Medicine and Radiology, Government Dental College Srinagar between august 2020 to February 2021. Three groups of study population were selected which are as follow:

Group 1:- this group was composed of 175 patients (69 males and 106 females) with oral lichen planus lesions. The mean age was 35.4 yrs. The mean duration of OLP lesion was 4.2

Corresponding Author:
Shamshad Begum
Tutor, Department of Oral
Medicine and Radiology, GDS
Srinagar, Jammu and Kashmir,
India

years. Diagnosis of the lesion was made on the basis of clinical examination and/or histopathological confirmation depending upon the patient consent. Clinically the patient with presence of erosive or atrophic lesions either with or without annular/ reticular pattern on buccal and labial mucosa was included in study. Histopathological biopsy tissue should display characteristic features for confirmation diagnosis. Complete extraoral as well as intraoral Examination was done. All patients were tested for presence/absence of HCV infection (Care diagnostic HCV test kit)

Group 2: This group was composed of 24 patients (16 males and 8 females) with known and confirmed diagnosis of HCV infection. The mean age was 34.7 yrs. These patients came for their dental complaints. Along with their chief complaint, the presence of Oral lichen planus was also evaluated. All 24 patients were questioned about their skin and oral symptoms related to lichen planus. Skin and oral mucosa were completely examined for determination of lesions. Diagnosis was made on the basis of clinical and histopathological examination.

Group 3: This control group consisted of 1500 patients (800 males and 700 females) who came for their routine dental treatment. The mean age was 44.7 yrs. The frequency of OLP and skin component of lichen planus had been detected in this population. The frequency of HCV infection among Kashmir population were taken from a study done by Ali I *et al* (South Kashmir) in 2018 as a reference for comparison in which overall prevalence of HCV infection was 1.9% [7].

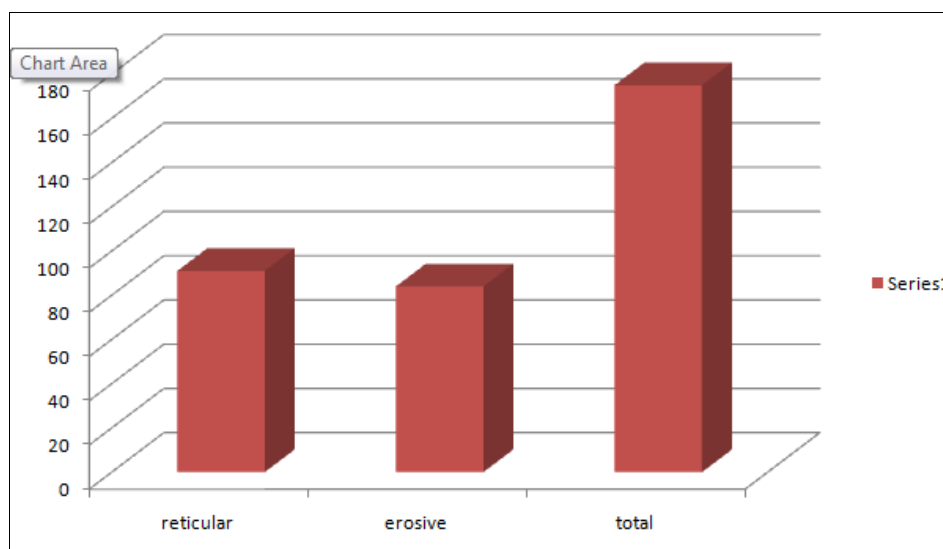
Data were properly recorded and analyzed by using Chi-squared test with aid of SPSS statistics 22.0. significance was set at Pvalue≤0.05.

Results

The results showed that in group 1, 175 patients with OLP lesions showed prevalence of HCV infection in only 1.7% of cases (Table1). Medical history revealed that 43 patients were diabetic, 37 were hypertensive and 19 were both diabetic and hypertensive. 21 cases reported thyroid problem,17 patients on other kind of systemic medications and 38 cases had no significant medical history. Buccal mucosa and tongue were most common sites and reticular (51.9%) and atrophic/erosive (48%) types were almost equal in frequency (Graph 1). Cutaneous lesions were seen in only 8 patients. Out of 24 cases of known and diagnosed HCV infection in group 2, only a single case reported with OLP lesion (reticular type) with overall frequency of OLP in HCV patients was 4.1% (table 1). Group 3 consisted of 1500 patients, frequency of oral lichen planus was 1.7% of total population. To determine the significance of these results, two statistical comparison were made. First is frequency of HCV in OLP patients and general population and secondly the frequency of OLP in HCV and general population. Overall frequency of HCV in general population of Kashmir was 1.9% (Ali I *et al.*) [7]. There was no statistical difference detected between the prevalence rate of both diseases with their control group. Hence there is no strong correlation between OLP and HCV as overall frequencies of both diseases were very less and insignificant with their respective control groups.

Table 1: Association of OLP and HCV infection in group1 and 2, frequency of OLP in general population (group 3).

GROUP	AGE (YRS)					Total
	20-29	30-39	40-49	50-59	>60	
Group 1(OLP) patients						
Number	17	68	35	29	26	175
HCV infection	0	2	0	1	0	3(1.7%)
Group 2(HCV) patients						
Number	2	9	7	4	2	24
OLP lesions	0	1	0	0	0	1(4.1%)
Group 3(controls)						
Number	186	254	410	306	344	1500
OLP lesions	7	9	4	4	2	26(1.7%)
HCV in OLP patients and HCV in General population (Ali I <i>et al</i> ⁷) Chi-squared value-0.01; P =0.97(non significant)						
OLP in HCV patients and OLP in General population Chi-squared value-1.20; P =0.2(non significant)						



Graph 1: Distribution of type of OLP lesions

Discussion

HCV infection can be asymptomatic, screening patients with Lichen Planus for this virus is important because it permits an early diagnosis and a better prognosis. Mokni *et al* were the first to note the association between HCV and lichen planus (LP) in 1991^[8]. Various researchers such as El-Kabir *et al* 1993; Scully *et al*, 1998; Roy and Bagg, 1999; Lodi *et al*, 2000^[9-12] have suggested that relation between the two diseases could be the result of genetic, environmental, geographic, or other factors.

In our study, the prevalence of HCV in OLP patients was 1.7% of cases and HCV in general population of Kashmir was 1.9% (Ali I *et al*)^[7]. Prevalence of OLP in HCV patients was 4.1% and oral lichen planus in general population was 1.7%. There was no strong correlation found between OLP and HCV. Bagan *et al*. 1994^[13] also founded no significant association between LP and HCV. The results are in consistent with the study done by Paulotsky *et al*^[14] who in 61 patients with HCV infection reported a 5% incidence of OLP which is quite similar to our study. 51 and Further Nagao Y (1996)^[15], Tucker *et al*. 1999^[16] and Prabhu *et al*. 2002^[17] also supported our results in which they stated that HCV infection was not associated with OLP.

Figueiredo LC (2002)^[18] in his study recorded the frequency of HCV in OLP patients was 8.8% which was significantly higher than in the general population which is 1.4% and the frequency of OLP in HCV patients (4.7%) was also significantly higher than that of the control group (0.6%). Our study results are partly in consistent with it as frequency of OLP in HCV patients was 4.1%. In contrast, Mokni M *et al* 1991^[8], Criber *et al*. 1994^[19], Alizari *et al*. 2016^[2] and Manomaivat *et al* 2018^[5] founded a strong correlation of HCV and OLP lesions.

The pathogenesis of association of OLP and HCV is not completely understood yet but there are several explanations either in favor of association or in contrast with their relation. HCV infection can precipitates an autoimmune process that lead to oral lesions^[20].

Conclusion

Our study founded no strong or significant correlation between HCV infection and oral lichen planus. Environmental, genetic or immunological factors can control the precipitation of oral lesions in HCV infected patients. Moreover Routine blood investigations, liver function tests and full medical screening related to liver should be carried out in these patients.

References

1. Canto AM, Müller H, Freitas RR, Santos PS. Oral lichen planus (OLP): Clinical and complementary diagnosis. *An Bras Dermatol* 2010;85:669-75
2. Alaizari NA *et al*. Hepatitis C virus infections in oral lichen planus: a systematic review and meta-analysis. *Australian Dental Journal* 2016;61:282-287.
3. Sarkis K Strak, FRCPa, Khalil I Al-Hamdi, FRCPa, Majid H Alabbod. A study of lichen planus and its association with hepatitis C infection. *Journal of Taibah University Medical Sciences* 2015;10(2):222-226.
4. Sugerman PB, Savage NW, *et al*. The pathogenesis of oral lichen planus. *Crit Rev Oral Biol Med* 2002;13:350-365.
5. Hasan *et al*. Oral lichen planus and associated comorbidities: An approach to holistic health. *J Family Med Prim Care* 2019;8:3504-17.

6. Lauer GM, Walker BD. Hepatitis C virus infection. *N Engl J Med* 2001;345:41-52.
7. Ali I *et al*. A Study on Prevalence of Hepatitis C among Adult Population in South Kashmir. *JK SCIENCE*. 2018;20(4):181-188.
8. Mokni M *et al*: Lichen planus and hepatitis C virus. *J Am Acad Dermatol* 1991;24:792
9. El-Kabir M, Scully C, Porter S *et al*. Liver function in UK patients with oral lichen planus. *Clin Exp Dermatol* 1993;18:12-16.
10. Scully C, Beyli M *et al*. Update on oral lichen planus: etiopathogenesis and management. *Crit Rev Oral Biol Medical* 1998;9:86-122.
11. Roy KM, Bagg J. Hepatitis C virus and oral disease: a critical review. *Oral Dis* 1999;5:270-277.
12. Lodi G, Carrozzo M, Harris K. *et al* Hepatitis C virus-associated oral lichen planus: no influence from hepatitis G virus co-infection. *J Oral Pathol Med* 2000;29:39-42.
13. Bagan V *et al*. Preliminary investigation of the association of oral lichen planus and hepatitis C (Oral Surg Oral Med Oral Pathol Oral Radiol Endod 1998;85:532.6)
14. Pawlotsky JM *et al*. Lichen planus and hepatitis C virus (HCV)-related chronic hepatitis: evaluation of HCV genotypes [letter]. *Br J Dermatol* 1995;133:666-7.
15. Nagao Y *et al*. Quantitative-analysis of HCV RNA and genotype in patients with chronic hepatitis C accompanied by OLP. *Eur J Clin Invest* 1996;26:495-8.
16. Tucker SC, Coulson IH. Lichen planus is not associated with hepatitis C virus infection in patients from England. *Acta Derm Venereol* 1999;79:378-379.
17. Prabhu S, Pavithran K. Lichen planus and hepatitis C virus (HCV)—is there an association?. *Indian J Dermatol Venereol Leprol* 2002;68:273-274.
18. Figueiredo LC, *et al*. Oral lichen planus and hepatitis C virus infection. *Oral Dis* 2002;8:42-46.
19. Criber B, Ndiaye I, Grosshans E. [Peno-gingival syndrome. A male equivalent of vulvo-vagino-gingival syndrome?]. *Rev Stomatol Chir Maxillofac* 1993;94:148-51.
20. Jubert C, Pawlotsky JM. *et al*. Lichen planus and hepatitis C virus related chronic active hepatitis. *Arch Dermatol* 1994;130:73e76.