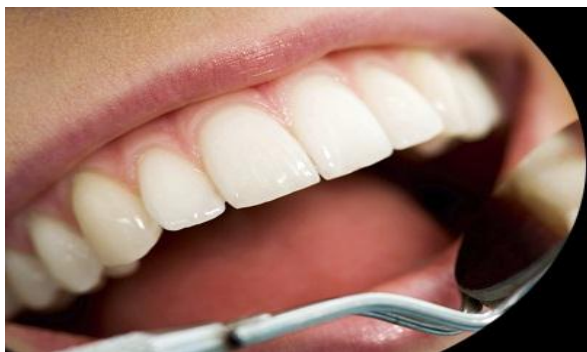



ISSN Print: 2394-7489  
ISSN Online: 2394-7497  
IJADS 2022; 8(1): 300-303  
© 2022 IJADS  
[www.oraljournal.com](http://www.oraljournal.com)  
Received: 11-11-2021  
Accepted: 14-12-2021

**Dr. Swati Aggarwal**  
Senior Lecturer, Shaheed Kartar  
Singh Sarabha Dental College,  
Ludhiana, Punjab, India

**Dr. Kanwardeep Sohi**  
Reader, Department of  
Prosthodontics, Sarabha Dental  
College and Hospital, Punjab,  
India

**Dr. Monica Goswamy**  
Professor, Department of  
periodontics, SDM College of  
Dental Sciences, Dharwad,  
Karnataka, India

**Dr. Sunil Kumar MV**  
Professor and Head, Department  
of Prosthodontics, Jaipur Dental  
College and Hospital, Jaipur,  
Rajasthan, India

**Dr. Barjinder Singh**  
Reader, Department of  
Prosthodontics, Uttarakhand  
Dental and Medical Research  
Institute, Dehradun,  
Uttarakhand, India

**Dr. Nishanth A Sudharson**  
Senior Lecturer, SKSS Dental  
College, Punjab, India

**Corresponding Author:**  
**Dr. Swati Aggarwal**  
Senior Lecturer, Shaheed Kartar  
Singh Sarabha Dental College,  
Ludhiana, Punjab, India

## Splinting: The prosthodontist way: Case report

**Dr. Swati Aggarwal, Dr. Kanwardeep Sohi, Dr. Monica Goswamy, Dr. Sunil Kumar MV, Dr. Barjinder Singh and Dr. Nishanth A Sudharson**

DOI: <https://doi.org/10.22271/oral.2022.v8.i1e.1442>

### Abstract

Dental splinting involves joining the crowns of two or more teeth by more or less rigid means: so that their relative movement is restricted and the forces applied to one of the splinted teeth are transmitted to the root system of all the linked teeth. Splinting has been used as a form of dental treatment for centuries. It remained a popular treatment for mobility until twentieth century, and was used as an integral part of periodontal treatment planning by many clinicians.

**Keywords:** Tooth, periodontium, fixed, removeable

### Introduction

Tooth stabilization and splitting have been accomplished since ancient civilizations to decrease tooth mobility, to replace missing teeth, and to improve form, function and esthetics. It is one of the earliest known examples in dentistry. The experience of numerous procedures for splitting indicates that this problem have received much attention. The problem of mobile teeth also attract the attention of the Father of Medicine Hippocrates, who used gold wire to stabilize teeth. Fouchard “the father of modern dental prosthesis“ in 1723 ligated and banded teeth of stabilize them <sup>[1]</sup>. Periodontitis is an inflammatory disease of the gingival and deeper periodontal tissues. Periodontitis is preceded and accompanied by gingivitis. A splint is a device used to immobilize the teeth and it is one of the oldest form of aids in periodontal therapy. Splitting of teeth, whether temporary or permanent, is an adjunctive therapy and not a cure to periodontal disease. By redistribution of forces on the affected teeth, the splint minimizes the effects caused by the loss the support <sup>[2]</sup>. Splitting stabilizes the teeth as a unit by including healthy teeth, and redirects the forces from individual teeth to the new unit as a whole. Including the healthier teeth results in a new increase in crown-root ratio and net decrease in force to the individual tooth, especially in the horizontal direction. Splitting transforms several individual teeth with varying degrees and patterns of mobility into a single functioning unit similar to a multirooted tooth, there by improving resistance of these teeth to force and altering the area of application and direction of force <sup>[3]</sup>.

There has been a great deal of debate about role of splinting in periodontal treatment, largely because the role of the splint has been misunderstood. The list of indication for splitting can be very long, but it usually includes teeth that have loosened over a period of time and missing teeth that require replacement. Other aims of splinting include protection of the tooth supporting tissues during the healing period after an accident or following surgery. Besides this, it helps in prevention of food impaction by stabilization of proximal contacts and to bring into function teeth that cannot be used to eat efficiently or in comfort without artificial support. It also helps in prevention of tipping, migration or supraeruption. Because an axially inclined force is the least traumatic, splitting provides for this type of force by controlling excessive mobility and thus, aids in the prevention of further breakdown of a seriously weakened periodontium, of tooth migration and of subsequent bite collapse.

The main objective of splinting in patients with advanced periodontal disease are to create an oral environment in which tooth mobility is normal or at least no longer increasing and the patient is able to function comfortably.

Teeth may be splinted as a part of phase I therapy, before periodontal surgery, utilizing temporary or provisional splints.

Permanent splints utilizing cast restorations may be placed as a part of the restorative phase of therapy.

### Classification of splinting

Teeth can be splinted by several methods. Splints used in clinical practice can be categorized as either removeable or fixed. The terms temporary or provisional refer to the durability of the appliance or the intended use. Describing an appliance as permanent is a relative term as all restorations fail in time and can be misunderstood by patients hence should be used with caution.

Major classification is based on the length of time the splint is to be used and whether provisional or long- term splinting is contemplated in conjunction with the periodontal prosthetics decided upon.

Minor classification are based on whether the technique of splinting involves removal of coronal tooth structure.

### According to Ross, Wiesgold and Wright (1968) it can be classified as <sup>[4]</sup>

- A. Temporary stabilization
  - Removable extra coronal splints
  - Fixed extra coronal splints
  - Intra coronal splints
  - Etched metal resin- bonded splints
- B. Provisional stabilization
  - Acrylic splints
  - Metal band and acrylic splints
- C. Long term stabilization
  - Removable splints
  - Fixed splints
  - Combination removable and fixed splints

### According to Grant (1988) <sup>[5]</sup>

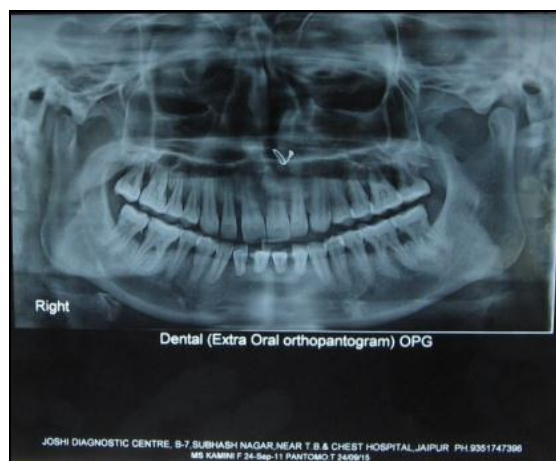- A. Temporary
  - a) External ( Extra coronal)
    - Ligature splints
    - Enamel bonding material
    - Welded band splints
    - Continuous splints
    - Night guards
  - b) Internal ( Intra coronal)
    - Acrylic splints
    - Composite splints
    - Acrylic full crowns
- B. Provisional splinting
 

Serve to stabilize a permanent mobile dentition from the time of initial tooth preparation until the time the dentition is periodontally stable enough for permanent restorations.
- C. Permanent splints
  - a) Removal – external
    - Continuous clasp devices
    - Swing lock devices
    - Over denture
  - b) Fixed internal
    - Full coverage
    - ¾ crowns and inlays
    - Posts in root canals
    - Horizontal pin splints
  - c) Cast metal resin bonded FPD ( Maryland Splints )
  - d) Combined
    - Partial dentures and splinted abutments
    - Removable fixed splints

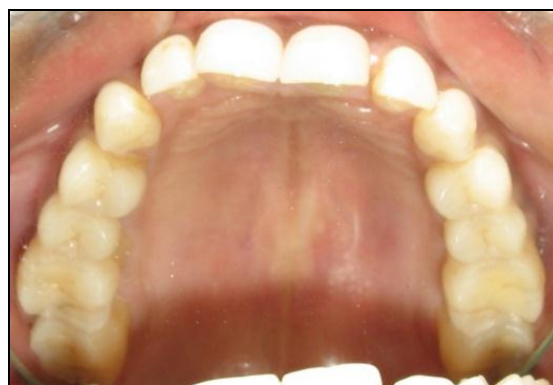- Full or partial dentures on splinted roots
  - Fixed bridges incorporated in partial dentures seated on posts and copings
- e) Endodontic

### Case report

A Female Patient named kamini, 26yrs, reported to Jaipur Dental College, and Hospital in 2011 with the chief complaint of unaesthetic appearance of her lower anterior teeth. On examination it was found that her lower permanent anterior incisors were missing, and had retained deciduous anteriors. On taking an Ortho Pantograph it was seen to have generalized bone loss with respect to both maxillary and mandibular arch, and presence of retained deciduous lower anterior teeth with missing lower permanent anteriors. (Fig.1) A diagnosis of generalized chronic periodontitis was made. Initially Phase I therapy such as scaling and root planning was done followed by occlusal adjustment. The management of tooth mobility was planned with the idea of placing ligature wire and splinting in relation to 16 to 26. Alginate impressions of the maxillary arch was made, ligature wire was braided to the desired length and adapted to the cast. After phase I therapy and pumice polishing, the teeth surfaces were thoroughly rinsed and dried. (Fig.2)

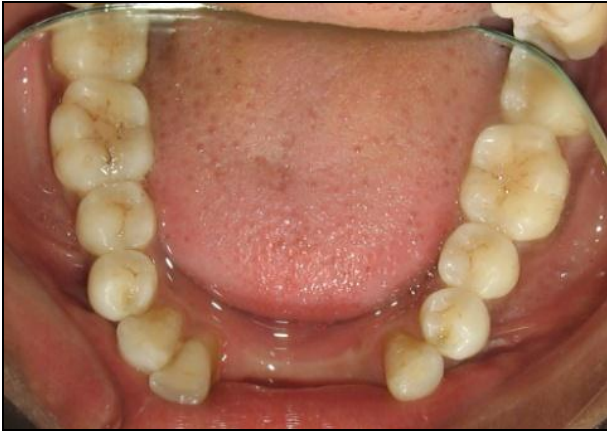


**Fig 1:** OPG showing retained deciduous

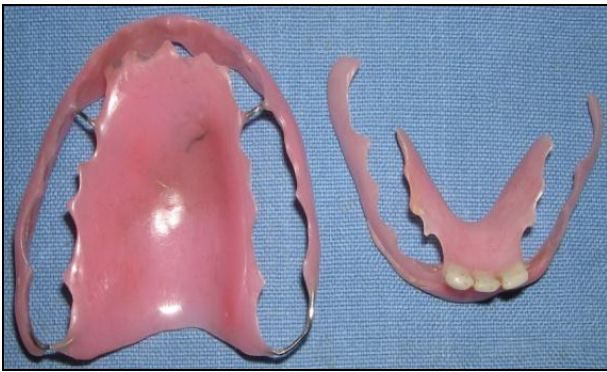

**Fig 2:** Maxillary Arch

The lingual surface were etched with 37% phosphoric acid for 20 seconds. Then the area is rinsed and dried thoroughly and bonding agent was applied and light cured for 20 seconds. Composite resin was then placed on the wire and light cured. Excess material was removed and finishing and polishing was done. The tooth were checked for mobility. Extraction of lower anterior deciduous teeth were done. (Fig.3)

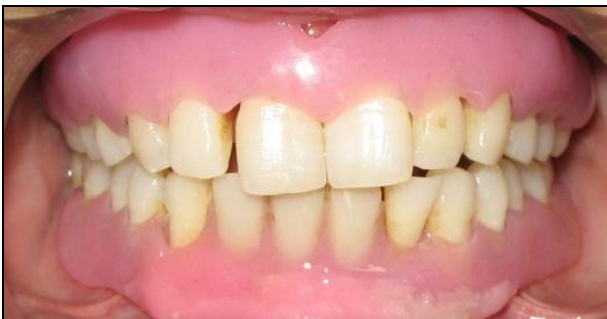

**Fig 3:** Extracted lower deciduous

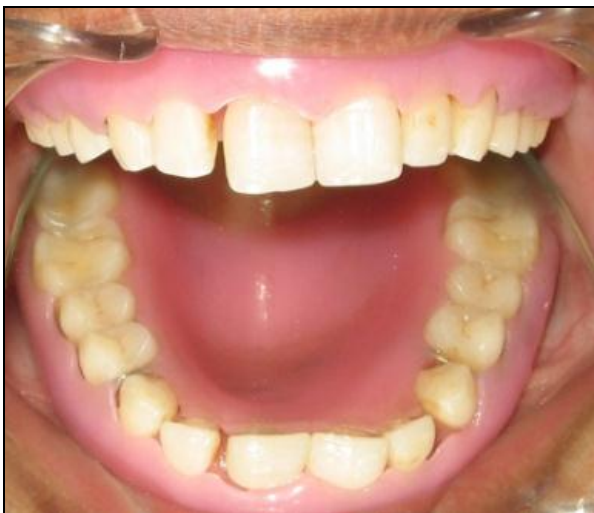

**Fig 4:** Removable appliance

A removable prosthesis was also designed for the patient for both the maxillary and mandibular arches and was given to the patient for use. (Fig.4,5,6)

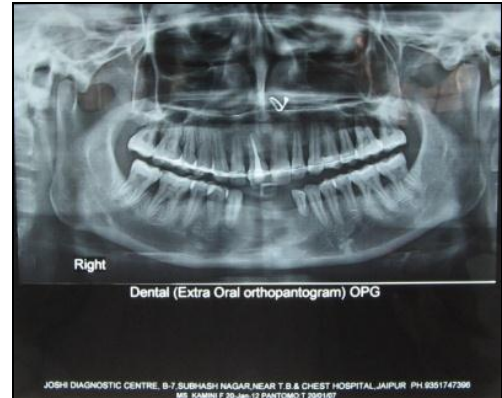

**Fig 5:** Removable appliance in mouth

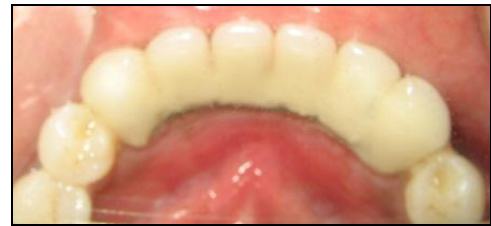

**Fig 6:** Maxillary view

Patient was given instructions on oral hygiene, advised to use interproximal brushes and was recalled after 3 months for review. (Fig.7)

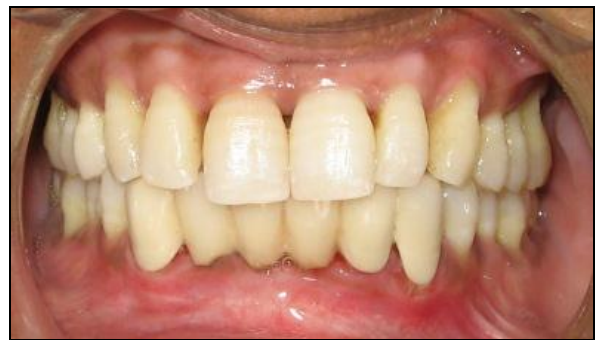

**Fig 7:** After splinting OPG

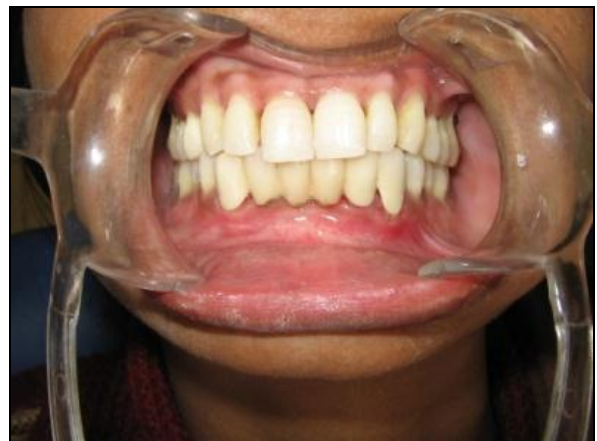

**Fig 8:** Fixed prosthesis

Patient reported after 3 months, and insisted for a fixed lower prosthesis as her wedding was finalized. Taking into consideration patient need a fixed prosthesis was planned from 33-43 i.e from canine to canine. Tooth preparation was done and impressions made, thereafter fixed prosthesis was made for the patient. (Fig.8,9,10)



**Fig 9:** Occlusal view



**Fig 10:** Final view

## Discussion

Dental splinting involves joining the crowns of two or more teeth by more or less rigid means, so that their relative movement is restricted and the forces applied to one of the splinted teeth are transmitted to the root system of all the linked teeth<sup>[6]</sup>. Dental splinting is an effective means of tooth stabilization. These splints are designed to reduce mobility and stabilize teeth located in the same dental arch. Maintaining oral health in and around fixed splints poses a significant challenge to the patient and the dental practitioner because access to teeth and visibility for plaque control and periodontal maintenance techniques require extra skill and effort. Effective personal plaque control, professional caries risk assessment, and periodontal maintenance is crucial to the longevity of the splint and health of the splinted teeth.

It is quite challenging to maintain a healthy, esthetically sound restorative result with splinting in anterior area. Splinting teeth together invariably creates an artificial esthetic barrier to the three dimensional appearance of tooth. For a splint to be successful the connector between the teeth need to have a specific thickness to provide strength in function and clinical durability. The incisal embrasure are critical to the esthetic silhouette of the incisal edges of both maxillary and mandibular anterior teeth. In case of porcelain metal restorations, the design of the tooth preparation must allow for adequate interproximal reduction so that the metal substructure can be placed lingual and be compatible with the occlusion<sup>[7]</sup>. Effective personal plaque control, professional caries risk assessment, and periodontal maintenance is crucial to the longevity of the splint and health of the splinted teeth. Post stabilization maintenance is equally important, as are the materials and procedures used in splint fabrication<sup>[8]</sup>.

## Summary and conclusion

Splinting therapy may be applied with bonded external appliances, intracoronal appliances, or indirect cast restorations to connect multiple teeth together with the goal of improving tooth stability. Unstable teeth may be due to a lack of periodontal support from bone, a lack of support from tooth loss, or the need to splint abutment teeth to support pontics. Indications for splinting are mobility of teeth that is increasing or impairs patient comfort, migration of teeth, or prosthesis where multiple abutments are necessary. Before considering splinting the etiology of the instability must be identified. Whenever occlusion is the cause, occlusal therapy is always performed first<sup>[9]</sup>. In addition, any inflammation of the periodontal supporting apparatus must be controlled before making a decision on splinting. When the teeth are splinted, all the teeth in the splint share the occlusal load to some extent. The rigidity of the splint and the number of teeth used determines how forces are distributed. The most common indication to splint mobile teeth is to improve patient comfort and provide better control of the occlusion if the anterior teeth are mobile. It is critical that adequate crown length on the teeth is being splinted so that the interproximal connectors do not impinge on the interdental papilla. Also, adequate space is needed between the connector and the papilla for access with dental floss anteriorly and an interproximal brush on posterior teeth<sup>[10]</sup>.

## References

1. Watkins SJ, Hemmings KW. An Introduction to the History of Dentistry, St. Louis: C.V. cited in: Periodontal splinting in general dental practices Dent update. 2000;27(1):278-285.

2. Schluger S, Yuodelis R, Page RC, Johnson RH. Periodontal Diseases. 2<sup>nd</sup> Ed., chapters 18, 19, 29 and 30, 1990.
3. Becker M, Kaiser A. The evolution of fixed splints. The A-Splint, Int. J Periodontal & Restorative Dentistry. 1998;18:277-285.
4. Ross SE, Weisgold A, Wright WH. Temporary stabilization. In Periodontal Therapy. 4<sup>th</sup> Ed. Edited by H.M. Goldman and DW Cohen. St. Louis, C.V. Mosby, 1986.
5. Grant D, Stern T, Listgarten M. Periodontics. 6<sup>th</sup> edition. Louis, MO: C.V. Mosby Co. 1988, 1056-1071.
6. Manson JD, Eley BM. Outline of Periodontics, 4<sup>th</sup> Edition, pg. 375.
7. Strassler HE, Graber DA. Anterior esthetic considerations when splinting teeth Dent Clin North Am. 1999;43:167-178.
8. Syme SE, Fried JL. Maintaining the oral health of splinted teeth Dent Clin North Am. 1999;43:179-196.
9. Lindhe J, Nyman S. Occlusal Therapy. In: Lindhe, J. (ed): Textbook of Clinical Periodontology, 2<sup>nd</sup> edition, Munksgaard, Copenhagen, 1989.
10. Carranza JR FA. Glickman's Clinical Periodontology, 6<sup>th</sup>ed. Philadelphia. W.B. Sanders Co., 1984.